Optometric Management of Visual Sequelae of Frontal Lobe-related Traumatic Brain Injury

- Lynn Lowell, O.D.[1]
- Allen H. Cohen, O.D.[2]
- Neera Kapoor, O.D., M.S.[2]

1. Plano, Texas
2. State University of New York, State College of Optometry, New York, NY

Abstract

Heightened awareness and interdisciplinary management of traumatic brain injury (TBI) sequelae have become a significant public health issue. Typical TBI sequelae include impaired: cognition, sensory processing, communication, and behavior. Sensory processing sequelae of TBI often include vision deficits since all four lobes of the brain impact visual function. This paper focuses on the frontal lobe's integral role in motor planning, visual executive function, and motor learning. A 26-year-old male, incurred a frontal lobe TBI when a nail gun misfired, damaging his left frontal and left parietal lobes. Optometric management is described for consequent aspects of compromised visual function.

Key Words

frontal lobe, motor planning, neuro-optometric vision rehabilitation, traumatic brain injury, vision therapy, visual executive function, visual perceptual processing

Lowell L, Cohen AH, Kapoor N. Optometric management of visual sequelae of frontal lobe-related traumatic brain injury. J Behav Optom 2010;21:3-11.

INTRODUCTION/ BACKGROUND

Definition and Epidemiology of Traumatic Brain Injury

Traumatic brain injury (TBI) is defined as a physiological disruption of brain function which is traumatically-induced, sudden, non-progressive and non-degenerative.[1,2] TBI requires the presence of at least one of the following: an altered mental state, loss of consciousness, post-traumatic amnesia, or focal neurological deficits.[1] Common causes of TBI include falls, motor vehicle accidents, collisions with moving or stationary objects and assaults.[3-10]

Approximately 1.4 million people in the United States incur TBI yearly in the civilian population alone.[3,4] This figure is likely an underestimate of the actual incidence of TBI since it includes only the reported events where patients presented to the hospital for treatment immediately post-injury.[3]

The burden to society is significant. Approximately 5.3 million people in the United States live with TBI and require some form of long-term assistance to complete their activities of daily living (ADLs).[3-10] Although many of these TBI survivors are young, they are often unable to work due to limitations from their brain injury. Therefore, tax payers bear the financial burden for direct medical fees and lost productivity estimated at approximately $60 billion in 2000.[3]

A range of 1.6 to 3.8 million sports- and recreation-related mild TBI (mTBI) where no immediate post injury attention is sought, is estimated to occur each year.[3,10] For those with mTBI who actually do seek medical attention and undergo neuro-imaging, the resolution of standard neuro-imaging, magnetic resonance imaging, and computed tomography are not necessarily sensitive enough to identify the principal neurological cause of TBI, diffuse axonal injury.[2-7,9-12] Consequently, many with mTBI are released from the hospital with normal neuro-imaging results and no neurological diagnosis.[3,4]

Regardless, those with mTBI who sought medical attention immediately, often experienced substantial deficits in ADLs, that may eventually require out-patient rehabilitation. Sequelae of mTBI may also include deficits in cognition, sensory processing, communication and behavior. These are collectively referred to as post concussion syndrome (PCS).[4] Since PCS may take hours to weeks to manifest in mTBI, many with mTBI are perplexed about the onset and etiology of their symptoms.[4]

The general symptoms[3,4] of TBI, while multiple and often vague (Table 1), may require patients to seek assistance from several physicians and rehabilitation healthcare professionals. Each professional is a member of the interdisciplinary rehabilitation healthcare team and often works in concert with one another in assisting patients regain function in daily living.[3,4]

Table 1. General Symptoms of Traumatic Brain Injury[3,4]

Pain/Systemic	Cognition	Sensory Processing	Communication	Behavior
- Fatigues easily - Lacks energy - Headache - Neck pain	- Difficulty with short term memory - Inability to sustain concentration - Difficulty making decisions - Decreased reaction time - Slower speed of processing/overt actions - Easily lost or confused with directions	- Dizziness/lightheadedness - Nausea - Increased sensitivity to lights - Blurred vision - Increased sensitivity to sounds - Increased sensitivity to distractions - Changes in smell/taste/ hearing - Tinnitus	- Slower speech - Aphasia	- Lacks motivation - Mood swings - Sleep disturbances

Table 2. Deficits of Vision Function, Principal Associated Symptom, and Percentage of Occurrence in a Visually-symptomatic TBI Sample[2]

Deficit of	Principal Associated Symptom	% of Occurrence in a Visually-Symptomatic TBI
Accommodation	Blur	41%[16-18]
Tear Film Integrity	Blur varies with blinking	19%[14,15]
Versional Ocular Motility	Slower, inaccurate reading skills	51%[16-18]
Vergence Ocular Motility	Eyestrain / diplopia eliminated with monocular occlusion	56%[16-18]
Visual-Vestibular Interaction	Loss of balance and dizziness with difficulty in visually-stimulating environments	56-58%[19]
Light-Dark Adaptation	Elevated light sensitivity	49%[19]
Visual Field Integrity	Missing a portion of vision	38%[20]
Visual-perceptual Processing	Slow reading	Not reported

Table 3. Visual Processing and the Lobes of the Brain[22]

Lobe	Role in Vision Function
- Occipital	- Geniculo-striate pathway receiving visual input via the optic nerves, the optic tracts, and the optic radiations, in addition to the associated visual areas
- Temporal	- Associated with perception, recognition, filtration, integration, and organization of auditory and visual stimuli - Associated with perception of sequential visual stimuli - Associated with memory and speech
- Parietal	- Associated with visually guided movements, spatial orientation, pattern recognition, perception of simultaneous visual stimuli, and figure ground perception
- Frontal	- Associated with general reasoning / problem solving, decision making / planning, spatial organization, planning and execution of visually-guided movements, visualization, emotional state, and speech

Vision and TBI

There are approximately 1.4 million TBIs incurred in the United States annually. Cohen,[2] on the basis of existing literature,[11-20] estimated 30%[2] present with neurological visual impairments (Table 2). These may, or may not, resolve over time without intervention. This estimate of 30% is plausible given the extensive cortical innervation throughout all four lobes of the brain that impact visual function and the fact that many with TBI present with axon damage traversing multiple cortical areas.[11-21]

The human brain obtains meaningful visual information with accurate input from the accommodative and ocular motor systems. Further, each lobe of the human cortex has certain designated responsibilities with respect to visual processing. Refer to Table 3 for a cursory overview of the four lobes and associated visual function.[22] Visual information may be compromised either due to anomalies of the accommodative and ocular motor systems, or anomalies in any of the four lobes of the brain. Disrupted visual information, in turn, may compromise higher-level visual processing. In other words, a sophisticated processing system is only as optimal as its input.[2]

Many ADLs, such as walking, reading, computer use, and driving, utilize vision as the primary sensory input. Further, many aspects of neuro-rehabilitation, including cognitive, vestibular, and occupational are also visually-driven. This preponderant vision dependence required for performing ADLs and neuro-rehabilitation techniques suggest that improving visual function may also benefit the patient's overall function. Depending upon the nature of the vision anomaly, vision rehabilitation may be incorporated as neuro-optometric rehabilitation, occupational therapy, or cognitive rehabilitation. Optimizing visual function may consequently facilitate other rehabilitative aspects, improve ADLs, and enhance overall quality of life for the patient.

The Frontal Lobe: Neuroanatomy and Neuro-Physiology Relating to Vision

The two main responsibilities of the frontal lobe in visual processing include visual

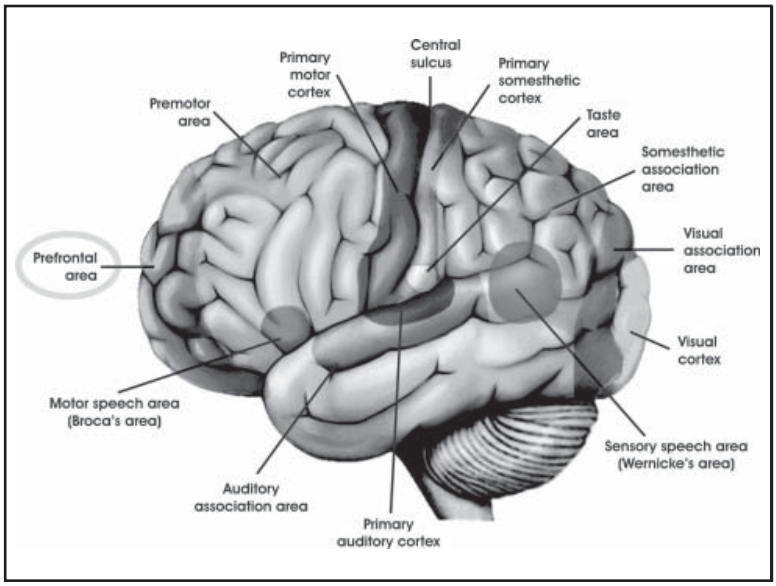

Figure 1: Neuroanatomy of the Frontal Lobe

Table 4: Clinical Dysfunctions Secondary to Frontal Lobe Injury[4,23,25-27,37]

Affected Area	Clinical Dysfunction
Primary Motor Cortex	Inability to execute an efficient visually guided movement
Premotor Cortex	Inability to gauge visual-spatial relationships and/or properly initiate motor planning
Frontal Eye Field	Inability to shift visual attention and gaze
Prefrontal Cortex	Deficits in executive function or combining information from the above areas in order to commence visually-guided movements such as saccadic eye movement
Broca's Area	Broca's expressive aphasia, impairing speech initiation while sparing language comprehension

executive functioning and motor planning.[23] The **frontal and occipital lobes** are particularly susceptible to insult with TBI.[24] Thus, understanding the role of the frontal lobe in visual processing is beneficial functionally as well as structurally in optometric evaluation and management.[2]

The **frontal lobe** is anterior to the central sulcus and is bordered by the lateral sulcus. It comprises approximately one third of the human brain. The main areas of the frontal lobe discussed in the following case report include the primary motor cortex, the premotor cortex, and the prefrontal cortex (Figure 1).[23,25]

The **primary motor cortex** (Brodmann's Area 4) lies immediately anterior to the central sulcus and runs parallel to the precentral gyrus.[23,25] It is somatotopically organized and is responsible for control of voluntary, skilled movements of the contralateral half of the body. It also controls the execution of visually-guided movements. Injury to this area can lead to vision deficits such as inefficient visually-guided movements (Table 4).[25-27]

The **premotor cortex (**Brodmann's Area 6) lies anterior to the primary motor cortex and contains the supplementary motor cortex. The premotor cortex, also somatotopically organized, is involved with evoking postural movements, as well as storing spatial information for the brain.[23,25] It is therefore responsible for programming and preparing for movements and postural changes in conjunction with the primary motor cortex, corticospinal, and corticobulbar fibers.[25] Injury to the premotor cortex may lead to vision deficits such as the inability to gauge visual-spatial relationships and properly initiate visual-motor planning (Table 4).[23,25-29]

The **prefrontal cortex,** which is the most extensive cortical region of the frontal lobe, lies anterior to the premotor cortex and is rich in connections with the parietal, temporal, and occipital lobes via long associated fibers.[23,25] The prefrontal cortex is responsible for higher-order cognitive functions including organization and motor planning actions, also referred to as visual executive functioning.[23] **Visual executive functioning** refers to the ability to accurately initiate, shift, or sustain eye movements by utilizing spatial information gathered from the premotor cortex. It also initiates visually-guided movements via the frontal eye fields and primary motor cortex.[30,31] Injury to the prefrontal cortex may impair versional ocular motility (i.e., fixation, pursuit, saccades) and vergence ocular motility (i.e., convergence and/or divergence)[30,31] (Table 4). Deficits of versional ocular motility may be perceived by the patient as either oscillopsia, blur while reading, and/or skipping lines or words while reading.

Two other areas of the frontal lobe are the frontal eye fields and Broca's area. They are important in planning of eye movements and speech, respectively. The **frontal eye fields** (Brodmann's Area 8) lie anterior to the premotor cortex on the lateral surface of the hemisphere.[25] This area of the brain is involved in fixation, saccades, and pursuit via a complex pathway involving the supplementary eye fields, basal ganglia, superior colliculus, cerebellum, thalamus, and brainstem.[25,26,30] It is this area that is responsible for voluntary oculomotor and saccadic eye movements. Unilateral damage to this area may result in an ipsi-lesional conjugate oculomotor deviation (ocular motor defect when looking to the side of the cerebral damage).[25] The proper execution of saccades, however, requires frontal eye field involvement to shift visual attention prior to the actual shift of gaze.[31] This process, known as **motor planning**, dictates how the decision is made prior to the actual shift of gaze. It regulates the shifting and sustaining of gaze.[29] Research shows that injury to the frontal eye fields may also result in impaired initiation of saccadic ocular motility (Table 4).[32]

Lastly, **Broca's area,** located in the inferior frontal gyrus of the left hemisphere, is in the motor speech area of the brain. Broca's area contains rich connecting fibers with the ipsilateral temporal, parietal, and occipital lobes to coordinate language function. Injury to Broca's area may lead to Broca's expressive aphasia, which is characterized by impaired speech initiation while sparing language comprehension (Table 4).[4,23]

Fundamentals of Motor Learning and Motor Planning

The neurophysiology and neuroanatomy of the frontal lobe is important because motor learning relies upon the prefrontal cortex. **Motor learning** involves establishing "an internal [visual spatial model] which represents the exact matching between perceived sensory and motor information."[33] Motor learning is typically established by an explicit phase and implicit phase.[33]

The **explicit phase**, or initial stage, of motor learning involves gathering sensory motor memories that are encoded in the dorsolateral prefrontal cortex. These early sensory motor memories are based upon trial and error, extremely dependent upon feedback, and have a high attentional demand.[33] Children demonstrate the explicit phase while progressing through various developmental stages. For example, with visual motor learning, infants and toddlers take in sensory information based on their surrounding visual cues and use tactile stimulation as feedback to confirm or negate their visual perception. Based on these experiences, children begin to develop a sensorimotor map with information about the spatial orientation of objects, localization of objects in relation to themselves, depth perception and even motor recruitment.[33]

Once infants and toddlers gather a significant amount of experiences, they begin to progress into the **implicit phase of motor learning.** This phase is more sophisticated and highly-skilled than explicit motor learning. The implicit phase of motor learning typically involves an "unintentional, non-conscious form of learning characterized by behavioral improvement" or improvement based on sensory information. Further, the implicit phase is rapid and automatic, involving widespread sensorimotor control.[33]

Ultimately, the goal of explicit and implicit phases of motor learning in vision is the transformation of visual cues into efficient motor responses or visually-guided movements, based on repetitious experiences of correct sensory-motor matches.[28,33-35] These learned behaviors are encoded in the prefrontal cortex. Insult to this area may present with inaccuracies in depth perception, ocular motility, or a poor command of spatial awareness.[33] Daily life implications may include: difficulties judging distances when driving, ambulating through busy streets without bumping into people or objects, and walking up and down stairs without mis-stepping.

Motor Planning in the Premotor Cortex

As stated previously, the premotor cortex is responsible for the programming of motor responses to be executed by the primary motor cortex.[25] Thus, neurons in the premotor cortex are responsible for initiating a virtual action plan based on the well-established sensorimotor map created in the dorsolateral prefrontal cortex.[33] The process of visualizing an action plan prior to its execution is referred to as **motor planning**. Motor planning utilizes working memory, which involves both temporary and long term memory storage. Working memory allows information to be gathered, maintained, and manipulated by the frontal cortex until it is ready for use in a behavioral task.[23,34-42]

Motor planning is evident in both saccadic and vergence ocular motility. Preceding any physical eye movement, the premotor cortex initiates a covert, or internalized, action plan based on the surrounding visual input. This covert plan requires a shift of visual attention, which precedes an overt shift of gaze executed by the frontal eye fields. Motor planning regulates covert decisions which are dependent on the visual spatial localization of objects. This process leads to the efficient overt execution of motor responses such as saccadic and vergence ocular motility.[23, 34-40]

The following case of severe frontal lobe-related TBI illustrates the common visual and general symptoms associated with TBI. Furthermore, it exemplifies the use of frontal lobe processes, specifically motor planning, visualization, and motor learning, as well as the relationship between frontal lobe processing and neural plasticity.[41,42] Finally, this case demonstrates the incorporation of frontal lobe processing in standard neuro-optometric vision rehabilitation techniques to optimize visual function, with possible associated improvements in other aspects of rehabilitation and ADLs.

CASE REPORT

Case History

CK, a 26 year old Indian male construction worker, was working on the job when the nail gun he was using backfired. A nail penetrated 3" into his left frontal and left parietal lobes. Subsequently, he was hospitalized for two weeks and underwent neurosurgery. Once released from the hospital, CK reported significant vision symptoms to his ophthalmologist. The ophthalmologist, in turn, referred CK to the Raymond J. Greenwald Rehabilitation Center at the State University of New York, State College of Optometry for neuro-optometric evaluation and management.

Table 5: Symptoms for CK Upon Initial Presentation in September 2007

Vision symptoms:
- Distance and near blur
- Eye strain and discomfort
- Words becoming "jumbled" while he is reading
- A necessity to re-read material for content
- Increased sensitivity to light
- Dizziness/feeling of spinning and overall imbalance
General symptoms:
- Fatigues easily
- Flat emotions
- Severe left-sided headaches with higher-level cognition and verbal communication
- Decreased speed of thought processing
- Short-term memory deficits
- Expressive aphasia
- Difficulty concentrating and easily distracted
- Easily confused with multiple-step instructions

Upon initial evaluation in September 2007, CK was involved in cognitive and speech therapy. His presenting symptoms are summarized in Table 5. His personal and family medical and ocular health histories were remarkable for hypertension, diabetes, thyroid disease, heart disease, cataracts, and glaucoma. CK was taking Acetominophen to control general body aches, valproic acid to control the severe headaches, and Antivert to control dizziness and vertigo. CK reported having no allergies to medications.

Optometric Examination

CK's optometric examination results revealed uncorrected distance visual acuities of 20/20 OD and 20/20 OS, but with delayed response times. His unaided near visual acuities fluctuated from 20/20 to 20/60 in each eye. There was no restriction of CK's extraocular motility for either eye, nor was there evidence of nystagmus in primary gaze for either eye. Confrontation visual field testing revealed no restriction in any meridian for either eye. Pupils were equally round and reactive to light, with no relative afferent pupillary defect. Ocular health evaluation of the anterior and posterior segments was unremarkable for each eye, except for a reduced tear break up time in each eye.

A refractive analysis revealed low hyperopia. Although retinoscopy indicated a correction of +1.75 DS at far, improved sustainable visual acuities with best corrected vision of 20/20 under monocular and binocular conditions was achieved at far with +0.50 DS in each eye and at near with +1.25 DS in each eye. Since multi-

Table 6. Vision Training Categories and Techniques Performed for CK. Techniques denoted with asterisks (*) are described in the discussion

Category	Techniques
Versional ocular motility (fixation, saccades, pursuit)	Monocular *Four corner wall saccades: incorporate motor planning and visual motor integration (VMI) *Standup rotating pegboard tracking: incorporate VMI Binocular Projected Hart Chart saccades Hart Chart coordinates Computerized fixation, saccades, and pursuit with visual motor integration
Vergence ocular motility	Brock string activities: Walk-up 2 bead jump duction 3 bead jump duction *3 bead jump duction with yoked prism Multiple string with yoked prism and balance board Multiple string with prism flips and metronome Two finger jump duction Pointer and straw Mirror superimposition *Vectogram vergence ranges with VMI Life savers with motor planning Computerized vergence training at near and projected with the following targets: Simultaneous perception Flat fusion Stereopsis Random dot Cheiroscope activities Fused base-in Van Orden Star training Fused base-out Van Orden Star training
Accommodation	Monocular accommodative facility in free space using lenses computerized *Monocular accommodative control using transparent eccentric circle Biocular accommodative facility with lenses Red rock Split spirangle vectogram Integrating accommodation and vergence while viewing base-out disparity vectograms using plus lenses and base-in disparity vectograms using minus lenses as jump duction.
Visual perceptual skills	Visual Perceptual / Visualization *Room mapping Parquetry Blocks Direct copy From memory / visualization Visual memory (simultaneous, sequential, or spatial) using pencil and paper, or computerized programs no delay and direct with a delay and direct *with a delay, direct, plus cognitive task

focal lenses are not typically prescribed for ambulation in those with TBI due to cognitive deficits and gait disturbances, two separate pairs of spectacles were prescribed for CK.[11,12] A distance spectacle prescription of +0.50 DS in each eye was given, as well as a separate reading prescription of +1.25 DS in each eye. Both spectacle corrections incorporated anti-reflective coating to partially alleviate the symptom of photosensitivity.

A sensorimotor vision evaluation confirmed comitancy of pursuit with no restrictions of extraocular motility. However, his eye movements were characterized by unsteady fixation, discomfort, and strain under monocular and binocular viewing conditions. Saccades were hypometric in all gazes, with increased latency, and a distinct deficiency in motor planning was evident under monocular and binocular viewing conditions.

Measurements for cover test, heterophoria testing, vergence ranges, and Keystone Visual Skills were consistent with convergence insufficiency, poor compensatory vergence ranges, decreased speed of fusional recovery, deficits of saccades, and decreased motor planning. Visual perceptual testing revealed severe deficits in: visual closure; visual sequential memory; visual simultaneous memory; slower speed of processing; difficulty with initiation of vision responses; and decreased motor planning ability. In addition, CK was diagnosed with convergence insufficiency, latent hyperopia, photosensitivity, and deficits of saccades. Two pairs of glasses and in-office neuro-optometric vision rehabilitation (minimum of 40 sessions) was prescribed to address his symptoms and clinical signs. These symptoms and signs were associated with convergence insufficiency, deficits of saccades, and the associated visual processing deficits (i.e. slower speed of visual processing; visual memory deficits; difficulty with initiation, visualization and motor planning).

Neuro-Optometric Vision Rehabilitation Paradigm

Four main categories of vision skills were involved in CK's neuro-optometric vision rehabilitation regimen: versional, ocular motor and vergence oculomotor, accommodative, and visual perceptual (Table 6). The principles involved in treating CK were the same as with a non-TBI vision therapy case,[43] except for the significant emphasis on re-training CK's visual executive function and motor planning ability. The vision therapy techniques used to train CK for ocular motility and accommodation are the same as are standardized and well described by Drs. Scheiman and Wick.[43] They were, however, modified to incorporate motor planning, initiation, and repeatability to address CK's needs related to the frontal lobe injury.[2] In terms of visual perceptual processing, visualiza-

Table 7. Phases of Neuro-Optometric Vision Rehabilitation for CK

Phase I Objectives
- Develop rapport: Define realistic goals, objectives, and guidelines
- Establish feedback scale (level of difficulty)
- Establish awareness of physiological diplopia
- Improve accuracy of: large angle saccadic; pursuit eye movement; monocularly then binocularly, including fixation with motor planning of ocular motility
- Normalize accommodative amplitude
- Develop plus lens acceptance, ability to relax accommodation, emphasize motor planning and initiation of accommodation
- Establish feeling of convergence and divergence
Phase II Objectives
- Improve small and moderate angle saccadic and pursuit eye movements with motor planning
- Normalize accommodative facility, emphasizing initiation and control of the accommodative system
- Develop robust positive/negative fusional vergence with visual motor integration
- Develop ability to visualize changes in versional ocular motility, vergence ocular motility, and accommodation
Phase III Objectives
- Decrease latency of saccadic/pursuit/vergence/accommodative ocular motility
- Reinforce accommodative stamina; improve accommodative-vergence interaction
- Automate ability to localize objects with precise visual spatial command
- Increase speed of overall visual processing

tion, accuracy, and speed; these were also trained for repeatability.[2]

The neuro-optometric vision rehabilitation techniques for each category were administered in phases and are listed in order of increasing difficulty, with the easiest techniques stated first (Table 7).[33] The principal difference between standardized vision therapy techniques and those used for CK is the incorporation of motor planning. This motor planning emphasizes visual executive function in all four categories of the listed visual skills and involves creating a sensorimotor mismatch.[2]

While there may be many ways of creating a sensorimotor mismatch, a common way of achieving this goal is by using yoked prisms. Yoked prisms create a sensorimotor mismatch by physically changing the angle that light enters the eye, shifting the virtual location of the visual spatial world in the direction of the apex of the yoked prisms. With the yoked prisms in place, the patient is asked to make an eye movement, which may be conjugate (i.e., pursuit or saccade) or disconjugate (i.e., convergence or divergence). By altering the visual (i.e., sensory) input and having the patient try to make the appropriate eye movement (i.e., motor response) for a given task, the concept of explicit motor learning is elicited. This places the patient in an unfamiliar visual environment that must be explored through visual-motor responses. Using physiological diplopia, localization, and visual motor feedback, the patient creates synapses that are needed to access his or her already established sensorimotor map. Modifying standardized training techniques with frontal lobe injury may seem elusive. Examples of how selected techniques were modified for CK's vision rehabilitation regimen in each of the four categories of vision rehabilitation are described below.

Versional Ocular Motility. Two specifically modified versional oculomotor therapies used in training CK include four corner wall saccades and stand up rotating pegboard tracking (Table 6). With these two techniques, the modifications used were visualization and motor planning. CK was instructed to first visualize the eye movement in his mind and then initiate the motor response. The motor response was initiated as part of the motor planning cascade of the frontal lobe to permit proper muscle recruitment prior to the execution of the motor response.

For example, motor planning with four corner wall saccades began with CK holding a laser pointer directed to the middle of the wall while he visually fixated the spot. Then, CK was instructed to visualize the area in the upper right hand corner of the wall, plan to move his eyes efficiently to that corner, and then make the efficient saccadic eye movement to that corner. Once the eye movement was made, CK was instructed to remain fixating on the corner for five seconds. After this time CK was instructed to move the laser pointer to the upper right hand corner where his eyes were fixated, allowing feedback based on a visually-guided movement. CK then repeated this movement for all of the four corners proceeding clockwise and then counter-clockwise. This activity reinforces visualization, with the creation of a virtual action plan in the premotor cortex, in conjunction with the sensorimotor map and motor feedback based on visual input, as well as motor planning.[28,29,33]

This concept of motor planning can also be applied to the stand up pegboard rotator. While holding a handheld medium sized loop in one hand, CK was instructed to track a single peg with his eyes and maintain the handheld loop centered around the peg as it rotates around on the pegboard in a clockwise or counterclockwise fashion. By holding the loop halfway between the rotating pegboard and CK's eye, a sensorimotor mismatch was created, such that a new experience may be encoded in his prefrontal cortex.[33] The mismatch here lies in the working distance of the loop. If the loop is positioned closer to the patient's eye, then the task is less challenging since the rotation of the loop is much smaller and correlates to the rotation of the eye itself. If the loop is positioned farther from the patient's eye and closer to the peg, then its rotational circumference is larger and more similar to that of the peg, than to that of the patient's eye. Therefore, if the loop is positioned in between the eye and the peg, its rotation matches neither that of the eye or the peg, forcing the patient to experiment in visual space, just as is evident in explicit motor learning.

Vergence Ocular Motility. Motor planning may be incorporated with vergence oculomotor therapy. It relies heavily upon proprioceptive feedback through visual motor integration and physiological diplopia. A few specialized vergence therapies of note include vectogram ranges with visual motor integration and Brock string three bead jump duction technique with yoked prism (Table 6).

When training with vectograms, the sensorimotor mismatch is inherent to each vectogram through the perception of SILO (smaller in, larger out). Since this visual perceptual concept may be foreign to the brain, a new visual environment where motor learning can take place is created. While holding a pointer, CK was instructed to localize the perceived vectographic image using the pointer. This ac-

Table 8: Sensorimotor Vision Data

Test Category	Test	Result September 2007	Result from April 16, 2009, unless noted otherwise	Comparison of the two examinations
Distance testing		**uncorrected**	**with +0.50 DS OD, OS**	**with +0.50 DS OD, OS**
	Cover test	4 prism diopters (Δ) exophoria	Orthophoria	Improved 4 prism diopters (Δ)
	Von Graefe	3 Δ exophoria	1 Δ exophoria	Improved 2 Δ
	Distance negative fusional vergence	x/8/2	x/12/6	Difference Range: x/+4/+4
	Distance positive fusional vergence	x/12/-4	x/12/6	Difference Range: x/same/+10
	Keystone visual skills (tests 1 and 4)	Moderate underconvergence beyond the expected range	Mild underconvergence within the expected range	Improved to be within the expected range
	Keystone visual skills (test 2)	No vertical deviation evident	No vertical deviation evident	Stable
Near testing		**uncorrected**	**with +1.75 DS OD, OS unless otherwise noted**	**with +1.75 DS OD, OS unless otherwise noted**
	Cover test	4 Δ exophoria	4-6 Δ exophoria, with sensorimotor fusion	Stable, gained awareness of sensorimotor fusion
	Von Graefe	7 Δ exophoria	9 Δ exophoria	Changed: -2 Δ
	Keystone visual skills (tests 10 and 11)	Moderate underconvergence beyond the expected range	Mild underconvergence within the expected range	Improved to be within the expected range
	Near negative fusional vergence	11/20/18	X/24/18	Difference Range: x/+4/same
	Near positive fusional vergence	6/18/0	X/18/9	Difference Range: x/same/+9
	Near point of convergence	5”/8”, with difficulty sustaining fusion	3” with good sensory motor fusion (03/26/09)	Improved 2” with sustainability
	Negative relative accommodation	+1.00D	+1.75D	Gained +0.75 D
	Positive relative accommodation	-0.50D	-1.00D	Gained -0.50 D
	Stereopsis	25” arc (improved to 20” arc with +0.50 DS OD,OS)	50” arc	Decreased 30” arc
	King Devick	#1 :58 seconds #2 :45 seconds #3: 48 seconds	#1 : 90 seconds #2 : 85 seconds #3: 95 seconds	#1 : 32 seconds longer #2 : 40 seconds longer #3: 47 seconds longer
Computerized Perceptual Testing	Visual closure	7/1/1 very low	8/6/9 below average	Improved 1/5/8
	Visual sequential memory	6/3/1 very low	4/5/3 very low	Stable -2/+2/+2
	Visual simultaneous memory	5/4/3 low	3/3/1 very low	Decreased -2/-1/-2

tive participation triggers explicit motor learning. It re-establishes connections to the sensorimotor map of the dorsolateral prefrontal cortex via visual motor integration.[33] Additionally by using physiological diplopia of the pointer to localize the image in space, it provides the brain with the necessary feedback regarding whether both eyes are processing visual information simultaneously.

Another example of creating a sensorimotor mismatch involves using vertical yoked prism of a moderate amount (e.g., 8 to 10 prism diopters) in conjunction with Brock String jump ductions with three beads. The yoked prism alters the angle of visual input and essentially changes sensory information. With CK motor learning was employed by requiring his eyes to verge appropriately at the bead of regard through the vertical yoked prism. CK received feedback, in the form of physiological diplopia of the strings. Additionally, by using the location of where the strings cross in reference to the bead of regard, provided CK with information as to whether his eyes were properly aligned on the target.

Accommodation. Motor planning may be used in accommodative training in the pre-presbyopic population through accommodative control, as evident with monocular accommodative control with transparent eccentric circles (Table 6). While one of CK’s eyes was patched, he was instructed to hold a single transparent eccentric circle card at approximately 40 cm viewing distance. CK was instructed to look through the eccentric circle with the unpatched eye and allow the figure to go out of focus (i.e., become blurred) by voluntarily relaxing his accommodative state. Once defocused, CK then had to increase his accommodative state until the print on the transparent eccentric circle card was

Table 9. Elements for Success in Neuro-Optometric Vision Rehabilitation

- Proper motor responses to a visual mismatch
- Feedback system
- Repetition
- Multi-sensory tasks, especially those involving visual motor integration
- Problem-solving, or higher-level cognition, tasks when possible
- Highly-motivating, detailed visual stimuli
- Active participation from a motivated patient

precisely focused using fine accommodative control and motor planning.

Visual Perceptual Processing. In this area, important concepts to emphasize, either in free space or using computerized programs, include visualization and speed of visual processing.

A technique for visualization that can be performed in free space, is room mapping (Table 6). CK was instructed to visualize a blueprint of his home and record in a tape recorder the exact steps and path taken to walk from one point to another in his home. Once the recording was completed, CK listened to his own instructions and followed the directions, while obtaining direct feedback as to whether the visualization was correct. When an error was made, CK returned to the starting point, re-visualized the path, and then re-commenced the task.

Speed of visual processing can be elicited by training sequential or simultaneous visual memory, using pencil and paper or via computerized programs. Simultaneous visual processing using a tachistoscope may be modified to employ a higher-level of processing by requiring increased working memory and manipulation in the frontal cortex. CK was instructed to remember the characters presented tachistiscopically and then manipulate them in his mind. Examples of such manipulations include performing math calculations in a given sequence of numbers and ultimately remembering the original sequence shown. One can also form two small words from the letters presented while remembering the original sequence of letters shown.

Vision Rehabilitation Results for CK

After 50 sessions of in-office vision therapy, using the regimen outlined in Tables 6 and 7 in conjunction with associated home-based activities, CK regained significant function in many of his ADLs. He reported improved fluidity of speech, improved speed of visual processing, and reduced light sensitivity. Despite persistent left-sided headaches with associated eye pain, CK reported being able to read for ten minutes consecutively with good comprehension of the material. Re-evaluation of optometric findings after 50 sessions of in-office vision rehabilitation revealed an improvement in many of his ocular findings (Table 8).

Although CK showed improvements in most areas, his overall scores on some tests decreased relative to his initial examination. It is important to understand that numeric grading systems are typically required to quantify improvement. In cases such a CK, the recorded numbers are not necessarily proportional to the quality of improvements experienced by the patient. Therefore, a balance between the patient's reported symptoms and changes in clinical signs upon re-evaluation is required in determining the degree of improvement evident in patients with TBI.

DISCUSSION

When designing a regimen for neuro-optometric vision rehabilitation, the etiology of the TBI guides the approach, goals and expected outcomes of therapy. The foundation of binocular vision is based on the utility of the sensorimotor map encoded by the prefrontal cortex.[33] Consequently, frontal lobe injury may impede the efficiency and sustainability of vergence ocular motility, versional ocular motility, and accommodation, as well as the overall speed of visual processing.

In the case of CK, his frontal lobe-related TBI impacted his motor planning and visualization. Therefore, concepts of motor learning, were incorporated in his vision rehabilitation regimen. To further ensure the re-acquisition of efficient sensorimotor visual function, CK's prior experiences encoded in his prefrontal cortex, were accessed via sensorimotor matching and neural plasticity reinforced through repetition.[33,38,41,42] The ultimate goal of CK's rehabilitation was to re-establish access to his sensorimotor map by creating sensorimotor mismatches. This simulated his motor learning.[2,33] A few additional elements were also required for success in vision rehabilitation (see Table 9).[2,38,41,42]

The elements in Table 9 are based on and enhanced by the existence of neural plasticity. Throughout the entire vision rehabilitation regimen, highly-motivating and detailed visual stimuli should be utilized when possible to elicit active participation from the patient. Developing proper motor responses to a visual mismatch facilitates explicit learning. It forces one to try to access the previously developed sensorimotor map in the dorsolateral prefrontal cortex. Providing feedback to the patient is a pre-requisite for motor learning. Feedback may be provided in many ways including instructions and comments from the optometrist, physiological diplopia, or visual-motor responses, to name a few. Repetition of the tasks is where home vision rehabilitation becomes important. This allows visual-motor responses where one gradually moves from explicit to implicit learning. As patients are able to perform basic vision tasks in-office, multi-sensory tasks may be introduced to help the basic vision task become more automated. In addition, problem solving or high-level cognition may be incorporated with visual processing techniques.

CK's success in vision rehabilitation was achieved by implementing the neuro-optometric vision rehabilitation regimen outlined in Tables 6 and 7, as well as incorporating the seven elements listed in Table 9, and employing the principles of motor planning, visualization, and motor learning.

CONCLUSIONS

With the increasing occurrence of TBI in the United States and the world, knowledge of associated symptoms and interdisciplinary management is of public health significance. Through diffuse axonal injury and shearing, deficits after TBI may be widespread. They can include deficits of cognition, sensory processing, communication, and behavior. With respect to sensory processing, vision deficits are manifest in approximately thirty percent of the reported TBI cases annually in the United States. This percentage is highly probable since all four lobes of the brain contribute to visual function and DAI often traverses across multiple lobes. Vision may likely become impaired secondary to TBI. This can include anomalies of: accommodation, tear film integrity, vergence, versional ocular motility, visual-vestibular interaction,

visual fields, light/dark adaptation, and visual speed of processing.

Even though all four lobes contribute to vision processing, the frontal lobe is integral to all aspects of visual function. It is responsible for coordinating the execution of visually-guided movements through motor planning, visual executive functioning, and motor learning. Distinct neurological pathways for accommodation, saccades, pursuit, and vergence exist. Neurological commonalities are evident with the frontal lobe-driven processes of motor planning and visual executive control. Both of these functions are integral in motor learning, neural plasticity, and neuro-optometric vision rehabilitation regimen.

Even with frontal lobe injury, neural plasticity remains applicable via repetition and experience-based motor learning. Neuro-optometric vision rehabilitation is viable as an option to optimize visual function in frontal lobe-related TBI, as was performed with CK. Although CK is an example of severe and penetrating frontal lobe TBI, his case demonstrates that specific vision rehabilitation techniques are not critical in those with frontal lobe-related TBI; rather the incorporation of underlying philosophies is far more important in neuro-optometric vision rehabilitation. Specifically these elements should include: motor learning, motor planning, visualization, speed of visual processing in executive functioning, and repetition. Consequent to improved visual function with neuro-optometric vision rehabilitation, the ability to perform other aspects of overall rehabilitation and ADLs may also improve. This should enhance the person's overall quality of life, as occurred with CK.

References

1. Mild Traumatic Brain Injury Committee of the Head Injury Interdisciplinary Special Interest Group of the American Congress of Rehabilitation Medicine. J Head Trauma Rehabil 1993;8:86-87.
2. Cohen A. Applied Concepts Course. Acquired Brain Injury. College of Optometrist in Vision Development Annual Meeting. Rancho Mirage, California. October 14-15, 2008.
3. Centers for Disease Control and Prevention. Traumatic Brain Injury. Available online at http://www.cdc.gov/ncipc/tbi/TBI.htm. Accessed 04/27/09.
4. National Institute of Neurological Disorders and Stroke. Traumatic Brain Injury: Hope Through Research. Available online at http://www.ninds.nih.gov/disorders/tbi/detail_tbi.htm. Accessed 04/27/09.
5. Langlois JA, Rutland-Brown W, Thomas KE. Traumatic Brain Injury in the United States: Emergency Department Visits, Hospitalizations, and Deaths. Atlanta: Centers for Disease Control and Prevention, National Center for Injury Prevention and Control; 2006.
6. Thurman D, Alverson C, Dunn K, Sniezek JE, et al. Traumatic brain injury in the United States: A public health perspective. J Head Trauma Rehabil 1999;14:602-15.
7. National Institute of Neurological Disorders and Stroke. Traumatic brain injury: Hope through research. Bethesda: National Institutes of Health; 2002 Feb. NIH Publication No: 02–158.
8. Corso P, Finkelstein E, Miller T, Fiebelkorn I, et al. Incidence and lifetime costs of injuries in the United States. Inj Prevention 2006;12:212-18.
9. Department of Veterans Affairs. Veterans Health Initiative, Traumatic Brain Injuries. Available online at http://www1.va.gov/vhi/docs/TBI.pdf. Accessed 04/27/09.
10. Brain Trauma Foundation. Facts about TBI in the US. Available online at http://www.braintrauma.org/site/PageServer?pagename=TBI_Facts. Accessed 04/27/09.
11. Kapoor N, Ciuffreda KJ. Vision disturbances following traumatic brain injury. Curr Treat Options in Neurol 2002;4:271-80.
12. Kapoor N, Ciuffreda KJ. Vision problems. In: Silver JM, McAllister TW, Yudofsky SC, eds. Textbook of Traumatic Brain Injury. Washington, DC: American Psychiatric Publishing, Inc., 2005;405-17.
13. Kapoor N, Ed. Neuro-optometry. Brain Inj Professional 2005;2.
14. Rutner D, Kapoor N, Ciuffreda KJ, Craig S, et al. Occurrence of ocular disease in traumatic brain injury in a selected sample: A retrospective analysis. Brain Inj 2006;20:1079-86.
15. Rutner D, Kapoor N, Ciuffreda KJ, Suchoff IB, et al. Frequency of occurrence and treatment of ocular disease in symptomatic individuals with acquired brain injury: A clinical management perspective. J Behav Optom 2007;18:31-36.
16. Ciuffreda KJ, Kapoor N, Rutner D, Suchoff IB, et al. Occurrence of oculomotor dysfunctions in acquired brain injury: A retrospective analysis. Optometry 2007;78:155-61.
17. Ciuffreda KJ. Kapoor N. Oculomotor dysfunctions, their remediation, and reading-related problems in mild traumatic brain injury. J Behav Optom 2007;18:72-77.
18. Ciuffreda KJ, Rutner D, Kapoor N, Suchoff IB, et al. Vision therapy for oculomotor dysfunctions in acquired brain injury: A retrospective analysis. Optometry 2008;79:18-22.
19. Craig SB, Kapoor N, Ciuffreda KJ, Suchoff IB, et al. Profile of selected aspects of visually-symptomatic individuals with acquired brain injury: A retrospective study. J Behav Optom 2008;19:7-10.
20. Suchoff IB, Kapoor N, Ciuffreda KJ, Rutner D, et al. The frequency of occurrence, types, and characteristics of visual field defects in acquired brain injury: A retrospective analysis. Optometry 2008; 79:259-65.
21. Suh M, Basu S, Kolster R, Sarkar R, et al. Increased oculomotor deficits during target blanking as an indicator of mild traumatic brain injury. Neurosci Let 2006;410:203-07.
22. Serendip. Brain Structures and their Functions. Available online at http://serendip.brynmawr.edu/bb/kinser/Structure1.html. Accessed 04/27/09.
23. Smith EE, Jonides J. Storage and executive processes in the frontal lobes. Sci 1999;283:1657-61.
24. Centre for Neuro Skills. Frontal Lobe Function. Available online at http://www.neuroskills.com/tbi/bfrontal.shtml. Accessed 04/27/09.
25. Crossman AR, Neary D. Neuroanatomy, 2nd Ed. Philadelphia: Churchill Livingstone, 2000.
26. Leigh RJ, Zee D. The Neurology of Eye Movements, 2nd Ed. Philadelphia: F.A. Davis Co., 1991.
27. Hoshi E, Tanji J. Differential involvement of neurons in the dorsal and ventral premotor cortex during processing of visual signals for action planning. J Neurophysio 2006;95:3596-616.
28. Hoshi E, Tanji J. Integration of target and body-part information in the premotor cortex when planning action. Nature 2000;408:466-70.
29. Nakayama Y, Yamagata T, Tanji J, Hoshi E, et al. Transformation of a virtual action plan into a motor plan in the premotor cortex. J Neurosci 2008; 28:10287-97.
30. Schall JD, Stuphorn V, Brown JW. Monitoring and control of action by the frontal lobes. Neuron 2002;36:309-22.
31. Hanes DP, Patterson 2nd WF, Schall JD. Role of frontal eye fields in countermanding saccades: Visual, movement, and fixation activity. J Neurophysiol 1998;79:817-34.
32. Curtis CE. Prefrontal and parietal contributions to spatial working memory. Neurosci 2006; 139:173-80.
33. Halsband U, Lange RK. Motor learning in man: A review of functional and clinical studies. J Physiol Paris 2006; 99:414-24.
34. Barco Al, Bailey CH, Kandel ER. Common molecular mechanisms in explicit and implicit memory. J Neurochem 2006; 97:1520-33.
35. Nobre AC, Gitelman DR, Dias EC, Mesulamb MM, et al. Covert visual spatial orienting and saccades: Overlapping neural systems. Neuroimage 2000;11:210-16.
36. Raos V, Evangeliou MN, Savaki HE. Observation of action: Grasping with the mind's hand. Neuroimage 2004;23:193-201.
37. Müller NG, Knight RT. The functional neuroanatomy of working memory: Contributions of human brain lesion studies. Neurosci 2006;139:51-58.
38. Klingberg T. Development of a superior frontal-intraparietal network for visuo-spatial working memory. Neuropsychologia 2006; 44:2171-77.
39. Moore T, Armstrong KM, Fallah M. Visuomotor origins of covert spatial attention. Neuron 2003; 40:671-83.
40. Beauchamp MS, Petit L, Ellmore TM, Ingeholm J, et al. A parametric fMRI study of overt and covert shifts of visuospatial attention. Neuroimage 2001;14:310-21.
41. Bailey CH, Kandel ER, Si K. The persistence of long-term memory: A molecular approach to self-sustaining changes in learning-induced synaptic growth. Neuron 2004;44:49-57.
42. Miniaci MC, Kim JH, Puthanveettil SV, Si K, et al. Sustained CPEB-dependent local protein synthesis is required to stabilize synaptic growth for persistence of long-term facilitation in aplysia. Neuron 2008;59:1024-36.
43. Scheiman M, Wick B. Clinical Management of Binocular Vision: Heterophoric, Accommodative, and Eye Movement Disorders. Philadelphia: Lippincott, Williams and Wilkins, 2nd edition, 2002.

Corresponding Author:
Lynn Lowell, O.D.
5934 W. Parker Rd., Ste 500
Plano, TX 75093
lynn.lowell.od@gmail.com

Date accepted for publication:
December 18, 2009